

EFFICACY OF NEURAL THERAPY IN THE TREATMENT OF NOTALGIA PARESTHETICA: REPORT OF TWO CASES

NOTALJİ PARESTETİKA TEDAVİSİNDE NÖRALTERAPİNİN ETKİNLİĞİ: İKİ OLGU SUNUMU

Mehpare FIRAT, MD¹ *, Yılmaz TURAN, MD²

¹Department of Physical Medicine and Rehabilitation, Ankara Etimesgut Şehit Sait Ertürk Government Hospital; Ankara - Türkiye

²Department of Dermatology, Ankara Beytepe Murat Erdi Eker Government Hospital; Ankara - Türkiye

Abstract

Notalgia paresthetica (NP) is a common sensory neuropathic syndrome with the symptoms of localized pruritus and dysesthesia of the unilateral infra scapular region. NP is a rarely reported T2-T6 sensory neuropathy whose etiology and treatment are not fully established and the clinical course consists of remissions and relapses.

We report two cases whom admitted to our clinic with a back burning sensation and we detected a hyperpigmented pruritic skin lesion in the scapular region. On inspection, hyperpigmented macular cutaneous lesions were seen on the scapular region. Neurological examination and biochemical blood tests were normal. Degenerative changes were observed on cervical and thoracic plain radiographs. The presence of hyperpigmented macular lesions on the scapular area of the patient and analgesic-resistant dorsal pain led us to the diagnosis of NP. We applied to these patients T2-T10 local segmental and to the hyperpigmented area with 1% lidocaine for treatment. After 2 week, the pain which was detected by a visual analog scale (VAS) declined. We applied the Leeds assessment of neuropathic symptoms and signs (LANSS) Pain Scale to analyse of of sensory dysfunction.

The aim of study is to determine the efficacy of treatment of notalgia paresthetica using neural therapy, assessing the degree of improvement in itching and burning sensation. Moreover, to evaluate the signs and symptoms associated with notalgia paresthetica. As a result, NP is a disorder that should be kept in mind in the presence of neuropathic upper back pain and hyperpigmented skin lesions. Neural therapy may be an alternative option that can be successfully applied in the treatment of these patients.

Key words: Notalgia paresthetica, neural therapy, treatment, diagnosis.

Özet

Notaljia parestetika (NP), sırt bölgesinde hiperpigmente kaşıntılı cilt lezyonuna eşlik eden, yanıcı sırt ağrısı, hipoestezi ve parestezi gibi nörolojik semptomların görüldüğü bir klinik durumu tanımlar. NP, etiyolojisi ve tedavisi tam olarak belirlenememiş, klinik seyri remisyon ve relapslardan oluşan, nadiren bildirilen bir T2-T6 sensoriyal nöropatidir.

Kliniğimize sırtta yanma hissi ile başvuran ve skapular bölgede hiperpigmente kaşıntılı deri lezyonu tespit ettiğimiz iki kadın olguyu sunuyoruz. İncelemede skapular bölgede hiperpigmente maküler kutanöz lezyonlar görüldü. Nörolojik muayene ve biyokimyasal kan testleri normaldi. Servikal ve torasik düz grafilerde dejeneratif değişiklikler izlendi. Hastanın skapular bölgesinde hiperpigmente makula lezyonlarının varlığı ve analjeziklere dirençli sırt ağrısı bizi NP tanısına götürdü. Bu hastalara tedavi için T2-T10 lokal segmental ve hiperpigmente alana %1 lidokain uygulandı. Tedavi sonrası vizüel analog skala (VAS) ile tespit edilen ağrı azaldı. Sensoriyal disfonksiyonun değerlendirilmesinde Leeds nöropatik semptom ve bulgular değerlendirmesini (LANSS) Ağrı Skalasını kullandık.

Çalışmanın amacı, nöral terapi kullanılarak notalgia parestetika tedavisinin etkinliğini belirlemek, kaşıntı ve yanma hissindeki iyileşme derecesini değerlendirmektir. Ayrıca, notalgia parestetika ile ilişkili belirti ve semptomları değerlendirmektir. Sonuç olarak NP, nöropatik sırt ağrısı ve hiperpigmente deri lezyonlarının varlığında akılda tutulması gereken bir hastalıktır. Nöralterapi bu hastaların tedavisinde başarıyla uygulanabilecek alternatif bir seçenek olabilir.

Anahtar kelimeler: Notaljia parestetika, nöralterapi, tedavi, tanı.

* Yazışma Adresi (Adress for Correspondance):

Mehpare Fırat, MD

Ankara Etimesgut Şehit Sait Ertürk Devlet Hastanesi,

Fiziksel Tıp ve Rehabilitasyon Bölümü Ankara - Türkiye

Tel: (0312) 552 55 00 - 0533 227 20 70

e-mail: drmeppure@gmail.com

Orcid id: <https://orcid.org/0000-0001-8375-3902>

Introduction

Notalgia paresthetica (NP) is a common sensory neuropathic syndrome with localized pruritus accompanied by the symptoms of burning, coldness, hypoesthesia, increased pain and tingling of the unilateral infra scapular region which often presents with localized hyperpigmentation of the affected area (1-4).

The prevalence of reported cases of NP is higher in women; in mid to late adulthood (3, 5). Mean age of onset in one large case series was 50-60 years (6). Although only a small number of reports are published, it is believed that NP is relatively common but perhaps underdiagnosed (7-9). Female gender may predispose to a worse severity of symptoms and increased BMI to a longer course of NP (5).

The diagnosis of NP is made on the basis of reported symptoms and specific area affected (10).

Spinal imaging is not necessary unless the patient has other neurological or musculoskeletal symptoms (1, 3, 6, 11).

There are a variety of treatment modalities including physical therapies (12, 13), pharmacological (14-16) and procedural treatments (17, 18), but there is lack of evidence to suggest that one treatment is superior to another.

NP is a rarely reported entity. It is believed that NP might not be rare in clinical practice, (5, 10) but it remains under-recognized, under-diagnosed, and therefore under-reported (2, 11). This case report provides neural therapy effect on NP management.

Case Report 1

A 55-year-old woman presented with a 10-year history of episodic pruritus of the left mid scapular region and skin sensitivity. The itch was present most of the day, occasionally waking her from sleep at night, and was aggravated by hot weather and hot showers. At times there was an accompanying sensation of "pins and needles or burning". The patient had hyperesthesia to light touch in this area. The pain was not continuous with exacerbating and remitting periods during the day.

The patient used antiinflammatory and musculorelaxant drugs as wells as physical therapy modalities and topical lidocaine gel and doesn't have relief with them. Her past medical and family history were unremarkable.

On physical examination, there were visible scratching marks and a slight hyper pigmented area in the left dorsal infra scapular region. She presented pain sensation or light touch sensation in this area. No associated muscle spasms were present at the time of the evaluation. We detected some fibrous bands at trapezius muscle. Her body mass index was 29.

The patient rated her "pain at the moment" as 6 on the Visual Analog Scale (VAS). When asked about the previous week, she rated her pain as 3 at its minimum, 7 at its maximum, and 5 on average. Her neuropathic pain severity rated by The Leeds assesment of neuropathic symptoms and signs (LANSS) as validated by Turkey (19). She rated her pain as LANSS: 23

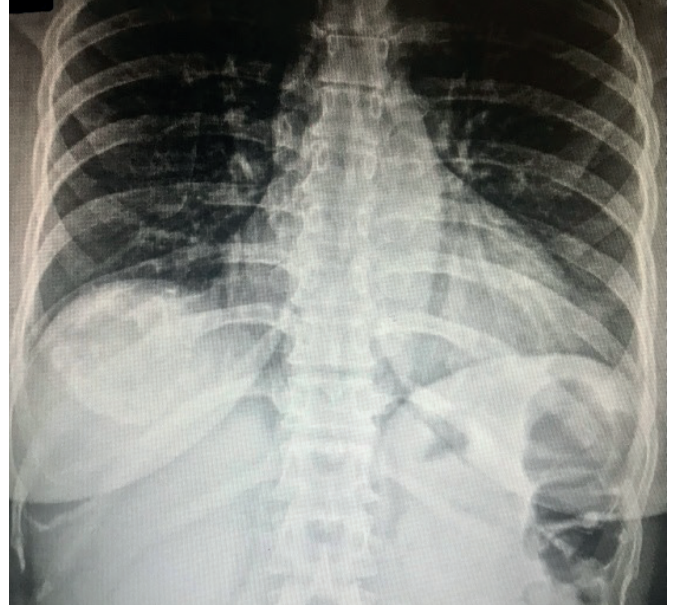


Figure 1 | Radiograph of the dorsal spine.

Radiograph of the dorsal spine showed a slight left thoracic scoliosis (Figure 1) and servical and dorsal degenerative changes. The patient's laboratory tests were normal.

The patient was diagnosed with NP based on her suggestive description of pain and the accompanying signs on the physical examination.

In these case itch treatments such as antihistamines or topical steroids, topical capsaicin, gabapentin and physical medical modalities as transcutaneous electrical stimulation (TENS) and ultrasound and all these medications failed.

We applied to this patient T2-T10 local segmental and to the hyperpigmented area with 1% lidocaine for treatment (Figure 2).

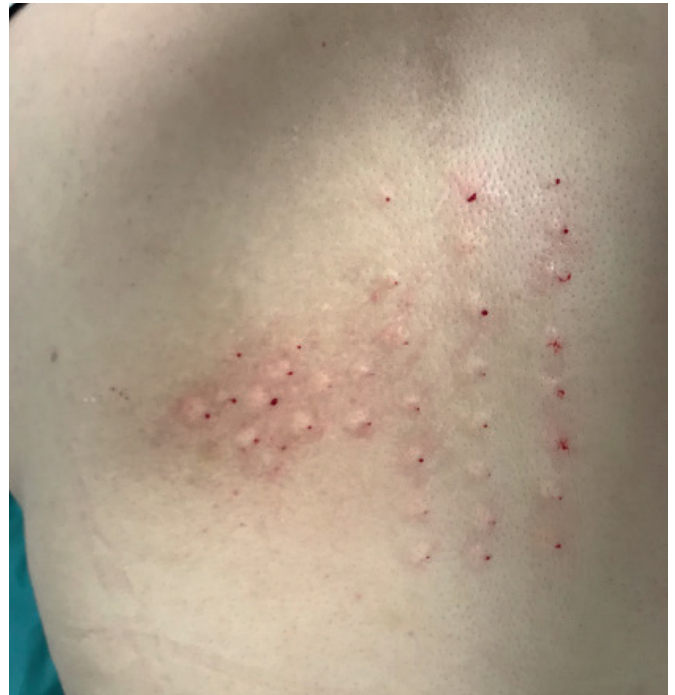

Figure 2 | The picture after treatment with T2-T10 local segmental and to the hyperpigmented area with 1% lidocaine .

After 2 weeks, the pain which was detected by a VAS declined from 7 to 3. There was no increase in pain level after the 4 week follow-up, and VAS as 3. We applied the LANSS to analyse of of sensory dysfunction and LANSS as 10.

Case Report 2

A 58 year-old woman presented with a 10-year history of episodic pruritus of the right mid scapular region and skin sensitivity. The itch was present most of the day, occasionally waking her from sleep at night, and was aggravated by hot weather and hot showers. At times there was an accompanying sensation of “pins and needles or burning”. The patient had hyperesthesia to light touch in this area. The pain was not continuous with exacerbating and remitting periods during the day.

The patient used antiinflammatory and musculorelaxant drugs as wells as physical therapy modalities and topical lidocaine gel and doesn't have relief with them. Her past medical and family history were unremarkable.

On physical examination, there were visible scratching marks and a slight hyper pigmented area in the right dorsal infra scapular region. She presented pain sensation or light touch sensation in this area. Associated muscle spasms were present at the time of the evaluation. We detected some fibrous bands at trapezius muscle. Her body mass index was 31.

The patient rated her “pain at the moment” as 7 on the Visual Analog Scale (VAS). When asked about the previous week, she rated her pain as 5 at its minimum, 7 at its maximum, and 6 on average. Her neuropathic pain severity rated by The Leeds assesment of neuropathic symptoms and signs (LANSS) as validated by Turkey (19). She rated her pain as LANSS: 23

Radiograph of the spine showed cervical (Figure 3) and dorsal (Figure 4) degenerative changes. The patient's laboratory tests were normal.

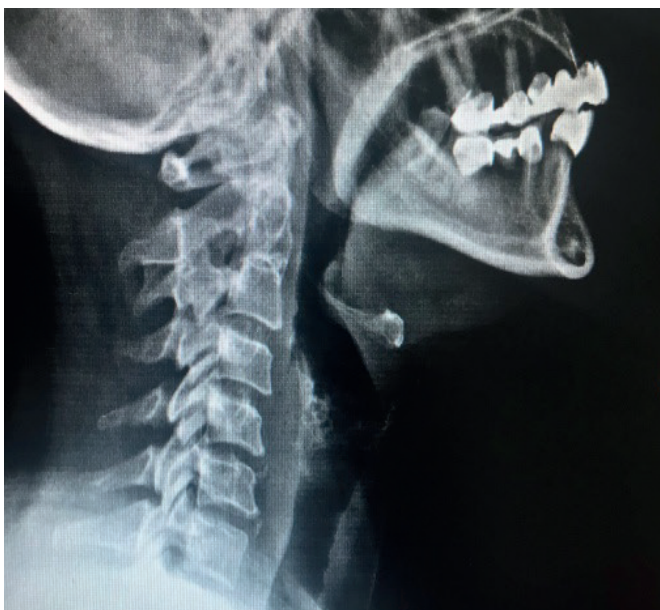

Figure 3 | Radiograph of the servical spine.

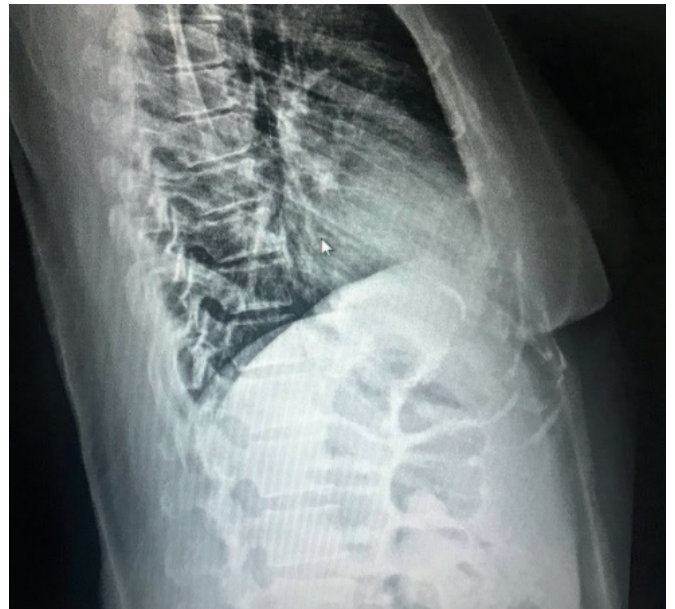

Figure 4 | Radiograph of the dorsal spine.

The patient was diagnosed with NP based on her suggestive description of pain and the accompanying signs on the physical examination.

In these case itch treatments such as antihistamines or topical steroids, topical capsaicin, gabapentin, amitriptyline and physical medical modalities as transcutaneous electrical stimulation (TENS) and ultrasound and all these medications failed.

We applied to this patient T2-T10 local segmental and to the hyperpigmented area with 1% lidocaine for treatment. After 3 weeks, the pain which was detected by a VAS declined from 7 to 4. There was no increase in pain level after the 6 month follow-up, and VAS as 5. We applied the LANSS to analyse of of sensory dysfunction and LANSS as 24.

Discussion

NP is a common sensory neuropathy caused by entrapment of the dorsal spinal sensory nerves. The pathogenesis was due to the damage or entrapment of the spinal sensory nerves from T2 to T6 as they emerge at right angles through the multifidus spinae paraspinal muscle (20).

A study by Savk and Savk 21 patients with NP showed over 60% had radiographic findings of degenerative vertebral changes or herniated discs in areas that corresponded to the dermatomal distribution of their symptoms. Several other studies have similarly shown an association between NP and significant spinal pathology (2, 3, 9).

NP is generally diagnosed on the basis of functional signs. Pruritus is the most common regular symptom; it is intermittent, often paroxysmal, and varying in intensity. It can be accompanied by pain, abnormal heating, burning or cold sensations, tingling, numbness (22, 23). The second main diagnostic criterion for NP is the specific area of the symptoms, i.e. D2±D6 dermatomes, corresponding to the subscapular paravertebral region.

The management of NP is difficult. Physical examination, medical history of the patient and radiologic findings must be the first step in evaluating a patient with NP.

Treatment options range from topical agents (capsaicin, corticosteroids, tacrolimus) and oral medications (gabapentin, oxcarbazepine, amitriptyline) to different treatment modalities (intra dermal botulinum toxin A, narrowband UVB light therapy, electrical muscle stimulation, transcutaneous electrical nerve stimulators, physical therapy, neuraltherapy) (1).

These therapies have shown varied improvement of symptoms, may be expensive, invasive or require continued long-term use, and in some cases have undesirable side effects.

Neural therapy may be an alternative option that can be successfully applied in the treatment of these patients (32).

Conclusion

NT may be a therapeutic option for NP and it has the advantage of being safe and relatively inexpensive; however, the most appropriate treatment for NP is currently not fully established (3, 7). The relief was significant with improved of quality of life.

Kaynaklar

- Shumway NK, Cole E, Fernandez KH. Neurocutaneous disease: neurocutaneous dysesthesias. *J Am Acad Dermatol* 2016; 74: 215-228.
- Ellis C. Notalgia paresthetica: the unreachable itch. *Dermatol Pract Concept*. 2013;3:3-6.
- Chiriac A, Podoleanu C, Moldovan C, et al. Notalgia paresthetica, a clinical series and review. *Pain Pract*. 2016;16:90-91.
- Perez-Perez LC. General features and treatment of notalgia paresthetica. *Skinmed*. 2011;9:353-358.
- Pagliariello C, Fabrizi G, De Felici B, et al. Notalgia paresthetica: factors associated with its perceived severity, duration, side, and localization. *Int J Dermatol* 2017; 56: 932-938.
- Raison-Peyron N, Meunier L, Acevedo M, et al. Notalgia paresthetica: clinical, physiopathological and therapeutic aspects. A study of 12 cases. *J Eur Acad Dermatol Venereol* 1999; 12: 215-221.
- Weber PJ, Poulos EG. Notalgia paresthetica. Case reports and histologic appraisal. *J Am Acad Dermatol* 1988; 18: 25-30.
- Raison-Peyron N, Meunier L, Acevedo M, et al. Notalgia paresthetica: clinical, physiopathological and therapeutic aspects. A study of 12 cases. *J Eur Acad Dermatol Venereol* 1999; 12: 215-221.
- Wallengren J, Klinker M. Successful treatment of notalgia paresthetica with topical capsaicin: vehicle-controlled, double-blind, crossover study. *J Am Acad Dermatol* 1995; 32: 287-289.
- Šitum M, Kolić M, Franceschi N, Pećina M. Notalgia paresthetica. *Acta Clin Croat*. 2018 Dec;57(4):721-725.
- Alai NN, Skinner HB, Nabili ST, Jeffes E, Shahrokni S, Saemi AM. Notalgia paresthetica associated with cervical spinal stenosis and cervicothoracic disk disease at C4 through C7. *Cutis*. 2010;85(2):77-81.
- da Cruz CM, Antunes F. Physical Medicine and Rehabilitation Role on Notalgia Paresthetica: Case Report and Treatment Review. *Am J Phys Med Rehabil*. 2018 Dec;97(12):929-932.
- Fleischer AB, Meade TJ, Fleischer AB. Notalgia paresthetica: successful treatment with exercises. *Acta Derm Venereol*. 2011 May;91(3):356-7.
- Pérez-Pérez LC. General features and treatment of notalgia paresthetica. *Skinmed*. 2011;9(6):353-8.
- Wallengren J, Klinker M. Successful treatment of notalgia paresthetica with topical capsaicin: vehicle-controlled, double-blind, crossover study. *J Am Acad Dermatol*. 1995;32(2 Pt 1):287-9. 10.1016/0190-9622(95)90152-3
- Andersen HH, Sand C, Elberling J. Considerable variability in the efficacy of 8% capsaicin topical patches in the treatment of chronic pruritus in 3 patients with notalgia paresthetica. *Ann Dermatol*. 2016;28(1):86-9. 10.5021/ad.2016.28.1.86
- Ochi H, Tan LX, Tey HL. Notalgia paresthetica: treatment with topical tacrolimus. *J Eur Acad Dermatol Venereol*. 2016;30(3):452-4. 10.1111/jdv.12830
- Williams EH, Rosson GD, Elsamanoudi I, Dellon AL. Surgical decompression for notalgia paresthetica: a case report. *Microsurgery*. 2010;30(1):70-2. 10.1002/micr.20702
- Goulden V, Toomey PJ, Hight AS. Successful treatment of notalgia paresthetica with a paravertebral local anesthetic block. *J Am Acad Dermatol*. 1998;38(1):114-6. 10.1016/S0190-9622(98)70552-3
- Yucel A, Senocak M, Kocasoy Orhan E, Cimen A, Ertas M. J Pain. 2004 Oct;5(8):427-32. Results of the Leeds assessment of neuropathic symptoms and signs pain scale in Turkey: a validation study. *J Pain*. 2004 Oct;5(8):427-32.
- Massey EW, Pleet AB. Electromyographic evaluation of notalgia paresthetica. *Neurology* 1981; 31: 642.
- Savk O, Savk E. Investigation of spinal pathology in notalgia paresthetica. *J Am CAD Dermatol* 2005; 52: 1085-1087
- Girolomoni G, Magni R, Magnoni C, Fantini F. Notalgia paresthetica. *G Ital Dermatol Venereol* 1992;127:553±556.
- Cerroni L, Kopera D, Soyer HP, et al. Notalgia paraesthetica. 'posterior pigmented pruritic patch' und makuloöse Amyloidose. *Hautarzt* 1993;44:777±780.
- Loosemore MP, Bordeaux JS, Bernhard JD. Gabapentin treatment for notalgia paresthetica, a common isolated peripheral sensory neuropathy [letter]. *J. Eur. Acad. Dermatol. Venereol*. 2007; 21: 1440-1.
- Savk E, Bolukbasi O, Akyol A et al. Open pilot study on oxcarbazepine for the treatment of notalgia paresthetica. *J. Am. Acad. Dermatol*. 2001; 45: 630-2.
- Goulden V, Toomey PJ, Hight AS. Successful treatment of notalgia paresthetica with a paravertebral local anesthetic block. *J. Am. Acad. Dermatol*. 1998; 38: 114-6.
- Williams EH, Rosson GD, Elsamanoudi I et al. Surgical decompression for notalgia paresthetica: a case report. *Microsurgery* 2010; 30: 70-2.
- Savk E, Savk O, Sendur F. Transcutaneous electric nerve stimulation offers partial relief in notalgia paresthetica patients with a relevant spinal pathology. *J. Dermatol*. 2007; 34: 315-9.
- Fleischer AB, Meade TJ, Fleischer AB. Notalgia paresthetica: successful treatment with exercises. *Acta Derm. Venereol*. 2011; 91: 356-7.
- Richardson BS, Way BV, Speece AJ. Osteopathic manipulative treatment in the management of notalgia paresthetica. *J. Am. Osteopath. Assoc*. 2009; 109: 605-8.
- Mülkoğlu C1, Nacı B1, Genç H1. An alternative in the treatment of notalgia paresthetica: neural therapy. *Int J Dermatol*. 2018 Sep;57(9):e70-e71.